



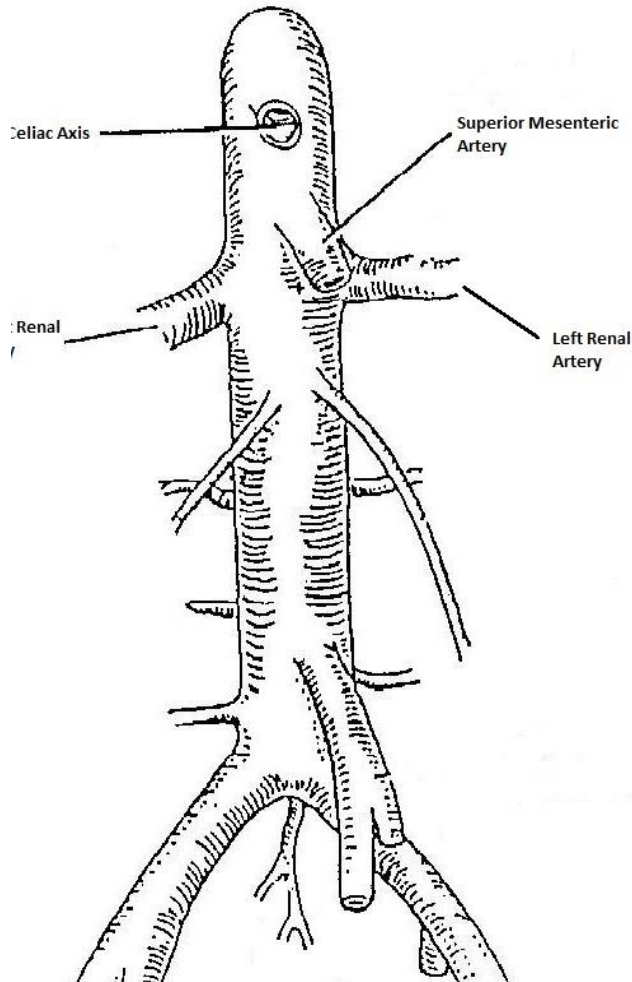
CARDIORISK AAA SCREENING

Patient Name: PETHAL, PEGGY Date: 12-08-2023

DOB: 04/24/1949 Sex: F

Referring Provider: SCOTT BELL

Vascular Technician: MICHELE WALTERS



Aorta Prox

2.3 cm Trans X 2.5 cm AP

Aorta Mid

1.9 cm Trans X 2.1 cm AP

Aorta Distal

1.8 cm Trans X 1.7 cm AP

Comments: No Abdominal Aortic Dilatation / Aneurysm was identified in the submitted images. There was a small amount of calcified plaque identified in the Abdominal Aorta.



